

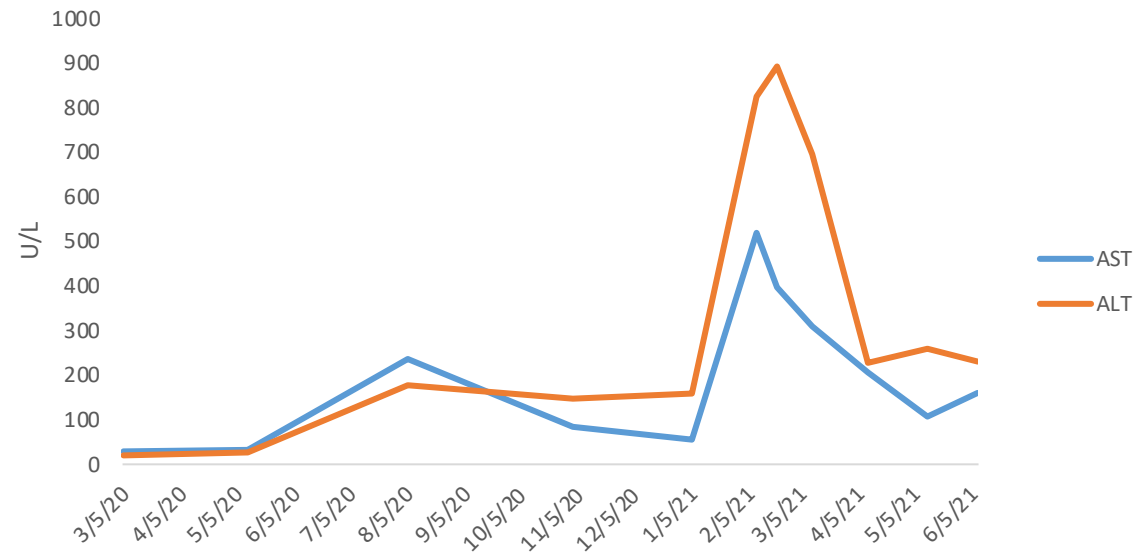
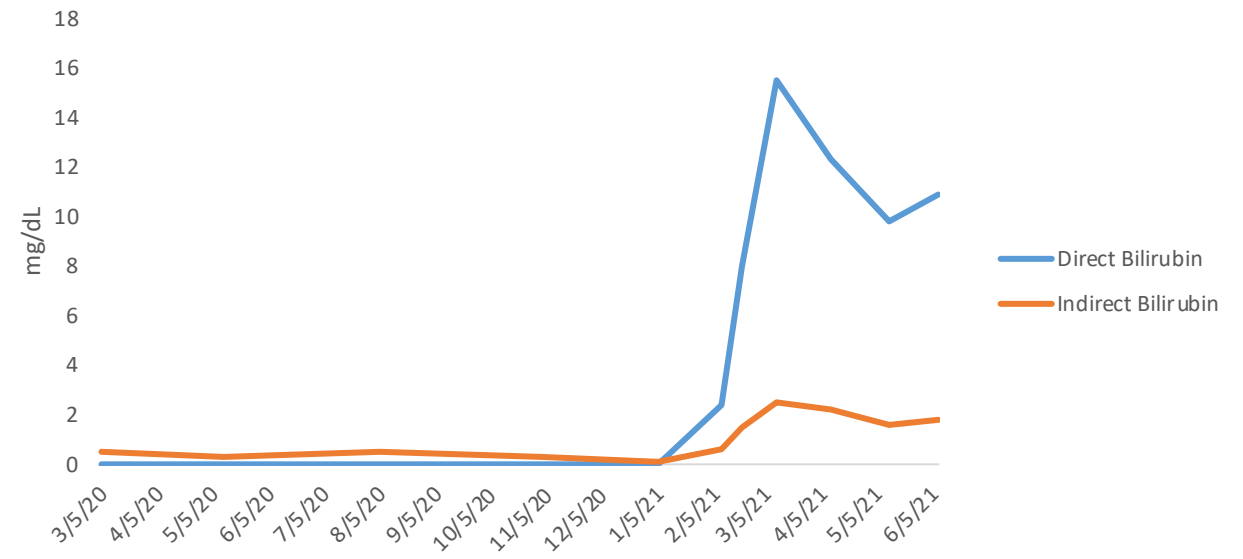
A**B**

FIGURE 1: (A) Liver transaminase and (B) direct and indirect bilirubin trend for Case 1- Patient underwent hematopoietic stem cell transplantation on 3/5/2020. He was positive for SARS-CoV2 by RT-PCR on 7/5/2020. On 8/14/2020, he was admitted for acute exacerbation of GI GVHD, followed by development of liver GVHD confirmed by biopsy on 4/14/2021.