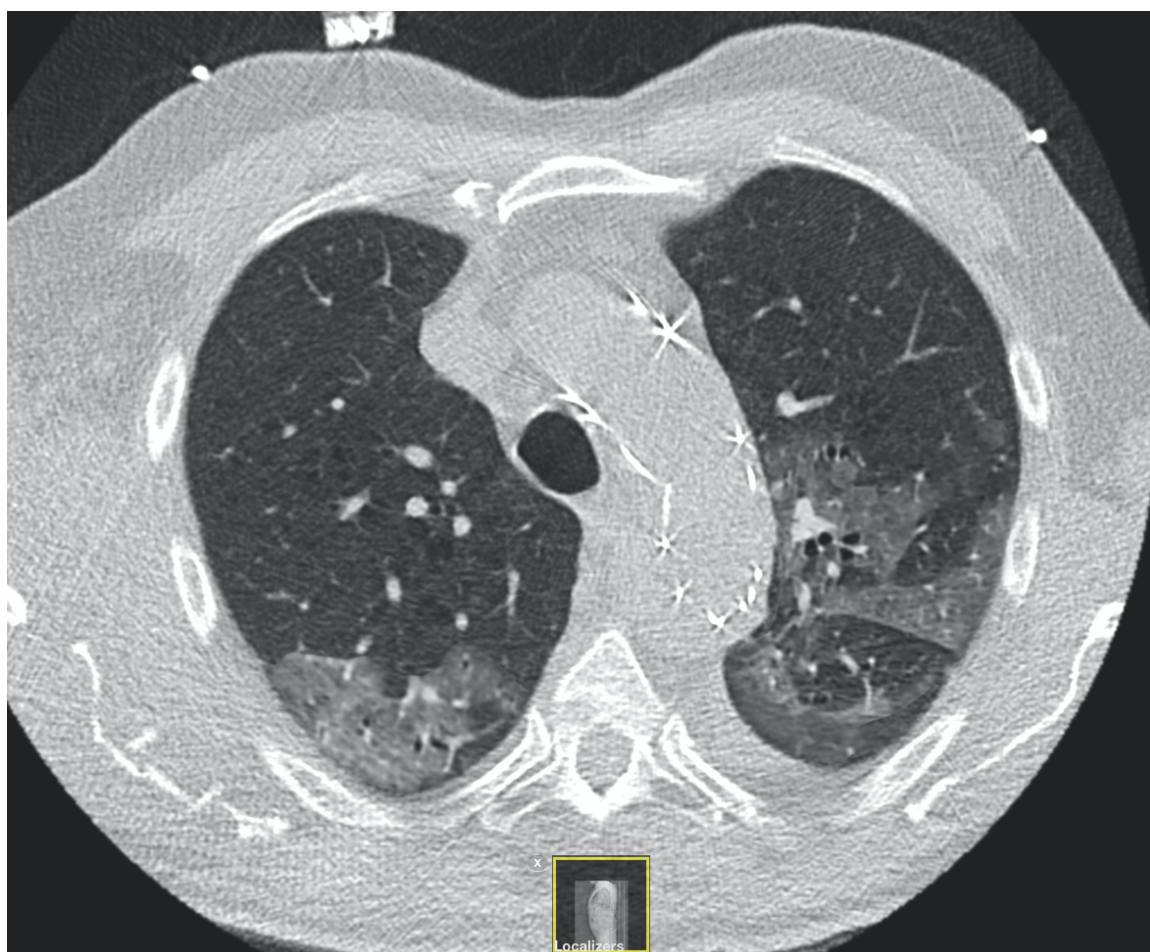


1 **Figure 2.** CTA after TEVAR in a COVID-19 patient showing typical ground glass opacities



2
3
4