

# Bacterial and viral coinfection among patients with COVID-19: a case report study

Elham Barahimi<sup>1</sup>, Parivash Davoodian<sup>1</sup>, Mehdi Hasani Azad<sup>1</sup>, Sahar defaee<sup>1</sup>, Ali Jandaghi<sup>1</sup>, and narjes seddighi<sup>1</sup>

<sup>1</sup>Hormozgan University of Medical Sciences

April 27, 2023

## Abstract

Background: Various studies suggest that coinfection with two or more respiratory pathogens is common. Coinfection with two viruses affects the host and exerts synergic effect as well and can influence the disease pathogenesis, immune system responses and treatment and outcome. Influenza and COVID-19 respiratory viruses have very similar symptoms and for this reason, bring about problems including delayed treatment and right diagnosis. This report describes three cases of coinfection with COVID-19 and influenza. Case Presentation: First case is a 46 years old Iranian housewife with the history of chronic coughs from two months ago who presented with exacerbation of coughs together with dyspnea. The second case is a 62 years old Iranian housewife with history of diabetes mellitus type 2 (DM-2) who presented with productive coughs, dyspnea and weakness. The third case is an Iranian pregnant housewife who presented with myalgia, fever and chills and dry coughs from a week ago. All three cases were tested positive for influenza and COVID-19 PCR tests. Conclusion: coinfection with two viruses can result in synergism of pathogens. Moreover, coinfection with a bacterial pathogen can make further problems. In these cases, coinfection with two viruses and mycobacterial infection in one of the cases along with comorbidities and pregnancy implied that these conditions entail immediate diagnosis as well as appropriate treatment choices.

## Bacterial and viral coinfection among patients with COVID-19: a case report study

### Authors' List

First author: Ms. Elham Barahimi,

Email: dr.e.barahimi@gmail.com

ORCID: 0000-0002-5601-5151

Affiliation: Infectious and Tropical Diseases Research Center, Hormozgan University of Medical Sciences, Bandar Abbas, Iran

Second author: Ms. Parivash Davoudian

Email: parivashdavoodian@yahoo.com

ORCID: 0000-0002-3303-7649

Affiliation: Infectious and Tropical Diseases Research Center, Hormozgan University of Medical Sciences, Bandar Abbas, Iran

Third Autor: Mr. Mehdi Hasani Azad

Email: mehdiassaniazad@gmail.com

ORCID: 0000-0001-5429-0056

Affiliation: Infectious and Tropical Diseases Research Center, Hormozgan University of Medical Sciences, Bandar Abbas, Iran

Fourth Author: Ms. Sahar Defaee

Email: sahardefaee137397@gmail.com

ORCID: 0000-0002-2468-4414

Affiliation: Assistant Professor of Pulmonology, Internal Medicine Department, Faculty of Medicine, Hormozgan University of Medical Sciences, Iran

Fifth Author: Ms. Narjes Sedighi

Email: narjes.seddighi80@gmail.com

ORCID: 0000-0001-5658-9238

Affiliation: Student Research Committee, Faculty of Para-Medicine, Hormozgan University of Medical Sciences, Bandar Abbas, Iran

Sixth Author: Ali Jandaghi

Email: djandaqi@live.com

ORCID: 0000-0002-4284-7037

Affiliation: Student Research Committee, Faculty of Medicine, Hormozgan University of Medical Sciences, Bandar Abbas, Iran

## Abstract

**Background:** Various studies suggest that coinfection with two or more respiratory pathogens is common. Coinfection with two viruses affects the host and exerts synergic effect as well and can influence the disease pathogenesis, immune system responses and treatment and outcome. Influenza and COVID-19 respiratory viruses have very similar symptoms and for this reason, bring about problems including delayed treatment and right diagnosis. This report describes three cases of coinfection with COVID-19 and influenza.

**Case Presentation:** First case is a 46 years old Iranian housewife with the history of chronic coughs from two months ago who presented with exacerbation of coughs together with dyspnea. The second case is a 62 years old Iranian housewife with history of diabetes mellitus type 2 (DM-2) who presented with productive coughs, dyspnea and weakness. The third case is an Iranian pregnant housewife who presented with myalgia, fever and chills and dry coughs from a week ago. All three cases were tested positive for influenza and COVID-19 PCR tests.

**Conclusion:** coinfection with two viruses can result in synergism of pathogens. Moreover, coinfection with a bacterial pathogen can make further problems. In these cases, coinfection with two viruses and mycobacterial infection in one of the cases along with comorbidities and pregnancy implied that these conditions entail immediate diagnosis as well as appropriate treatment choices.

**Keywords:** COVID-19, influenza, coinfection, tuberculosis, oseltamivir, remdesivir

## Background

Coronavirus disease 2019 (COVID-19) was first reported in Wuhan, China. This is the consequence of SARS-CoV-2 virus. As prevalence of the disease increased all around the world, by March 11, 2020, World Health Organization (WHO) declared it as a pandemic disease [1]. Influenza virus is an encapsulated single-stranded RNA virus which infects the epithelium of the airways. Influenza type-1 can result in seasonal flu and about 5-10% of adults will be exposed to it annually [2]. Clinical presentation of COVID-19 is similar to that of influenza virus infection. Influenza is known to cause coinfection with other respiratory infections [3]. Influenza infection presents with symptoms such as high-grade fever, cough, myalgia and rhinorrhea [4].

Studies suggest that coinfection with many respiratory pathogens is common. Coinfection with two viruses can affect the host and bring about synergism and as a result, considerably influence the disease pathogenesis, immune system responses as well as the treatment outcome [2]. Respiratory viral infections such as COVID-19 and influenza have very similar symptoms which can make problems such as delayed diagnosis and treatment [5]. Here, we report three cases of COVID-19 and influenza coinfection whose PCR tests were positive for both diseases. After treatment, all three cases were discharged with satisfactory general conditions.

## Case Report

### Case 1

A 46 years old Iranian housewife with a history of chronic coughs since two months ago presented with exacerbation of coughs together with dyspnea. The patient had a history of liver cirrhosis secondary to autoimmune hepatitis and it was being treated with UDCA, azathioprine, spironolactone, and furosemide. The patient has a history of fever, chills, myalgia, bone pain, and exposure to a symptomatic person. She has been a smoker and has received two doses of the COVID-19 vaccine. Vital signs were as follows: temperature of 36.5°C, heart rate of 75/min, blood pressure of 110/80mmHg, a respiratory rate 18 of breaths per minute, and SPO2 of 95%.

In physical examination, the conjunctiva was pale and coarse crackle was auscultated in both lungs. Based on the history and symptoms of the patient, PCR tests for COVID-19 and influenza were taken which were positive simultaneously. Patient treatment started with oseltamivir 75mg per-oral (po) every 12 hours and remdesivir 200mg STAT and 100mg daily through IV-line. In spiral chest CT-Scan, there were multiple patchy ground-glass opacities together with consolidations in both lung fields some of them are cavitated especially in RUL more in favor of TB, and LUL appearance is suggestive of superinfection of COVID-19 or influenza viral pneumonia (Fig. 1). Acid-Fast Bacteria (AFB) test was done for the patient which yielded a 3+ result. Based on tuberculosis diagnosis, fixed-dose combination antituberculosis drug therapy with three 'tabs started.

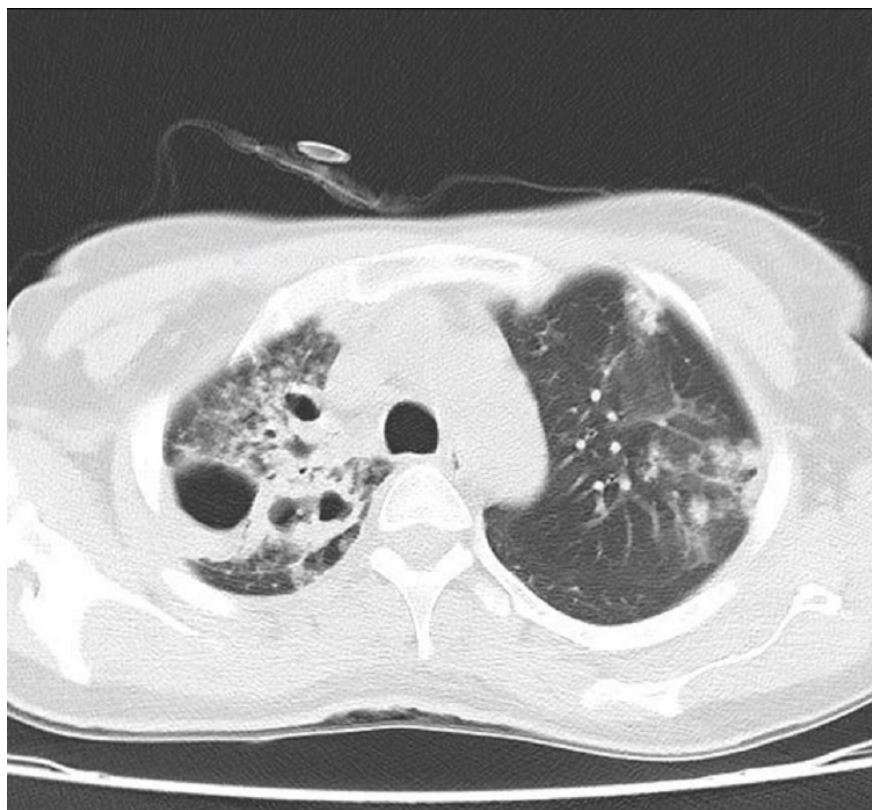

Fig. 1: Chest CT-scan of the first case suggestive of TB and superinfection of COVID-19 or influenza viral pneumonia

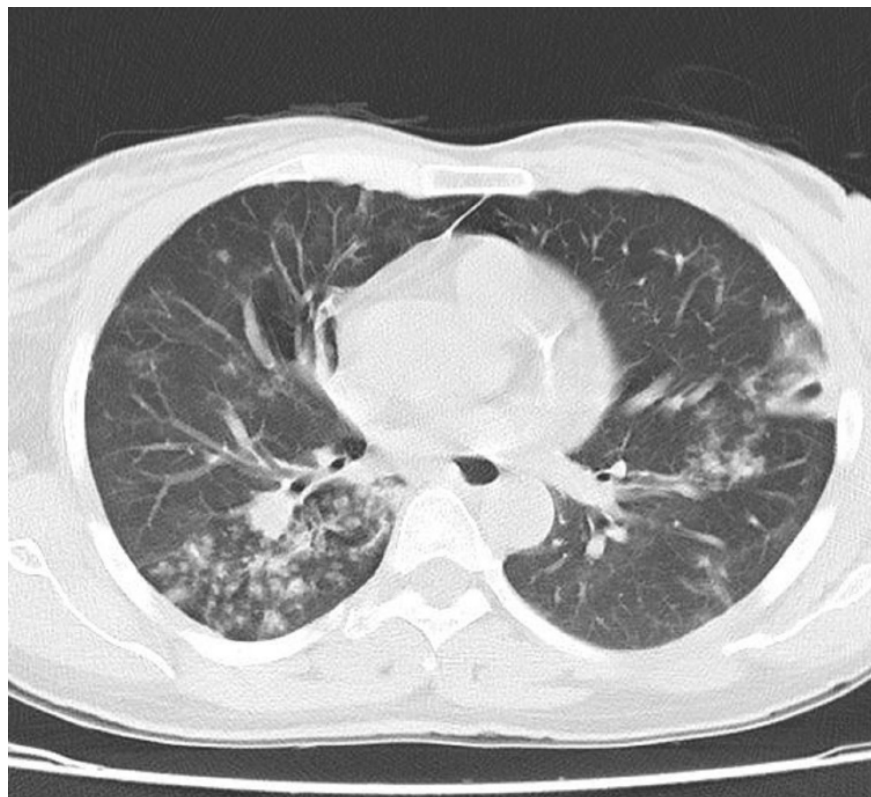


Fig. 2: Centrilobular micronodules and tree-in-buds in the superior segments of RUL and RLL, in favor of TB

After relative improvement of dyspnea and coughs, patient was discharged with relatively good conditions and was advised to continue treatment with anti-TB and outpatient follow-up. A week after discharge, dyspnea and coughs improved relatively.

## Case 2

A 62 years old Iranian housewife presented with productive coughs, dyspnea, and weakness. The patient has a history of DM-2 which is being controlled by metformin, gliclazide, pregabalin, and atorvastatin. a week before the visit ago, the patient was hospitalized for three days with fever and chills, and myalgia. After discharge, coughs and dyspnea were exacerbated. The patient has a history of contact with a symptomatic person. She received two doses of the COVID-19 vaccine. Vital signs were as follows: temperature of 36.9°C, heart rate of 102/min, blood pressure of 110/80 mmHg, a respiratory rate 24 of breaths per minute and SPO2 of 90%.

In physical examination, the conjunctiva was pale and the crackle was auscultated in both lungs. Based on the history and symptoms of the patient, PCR tests for COVID-19 and influenza were taken which were positive simultaneously. In spiral chest CT-Scan, there were bilateral diffuse tubular bronchiectasis, subpleural involvement, and consolidation more suggestive of influenza. However, the presence of opacity as well as ground-glass opacity and subpleural lines were more suggestive of COVID-19 infection. Oseltamivir 75mg PO every 12 hours and remdesivir 200mg STAT and 100mg daily through IV-line together with cefepime 1g every 8 hours and vancomycin 1g every 12 hours both via IV-line started for the patient.

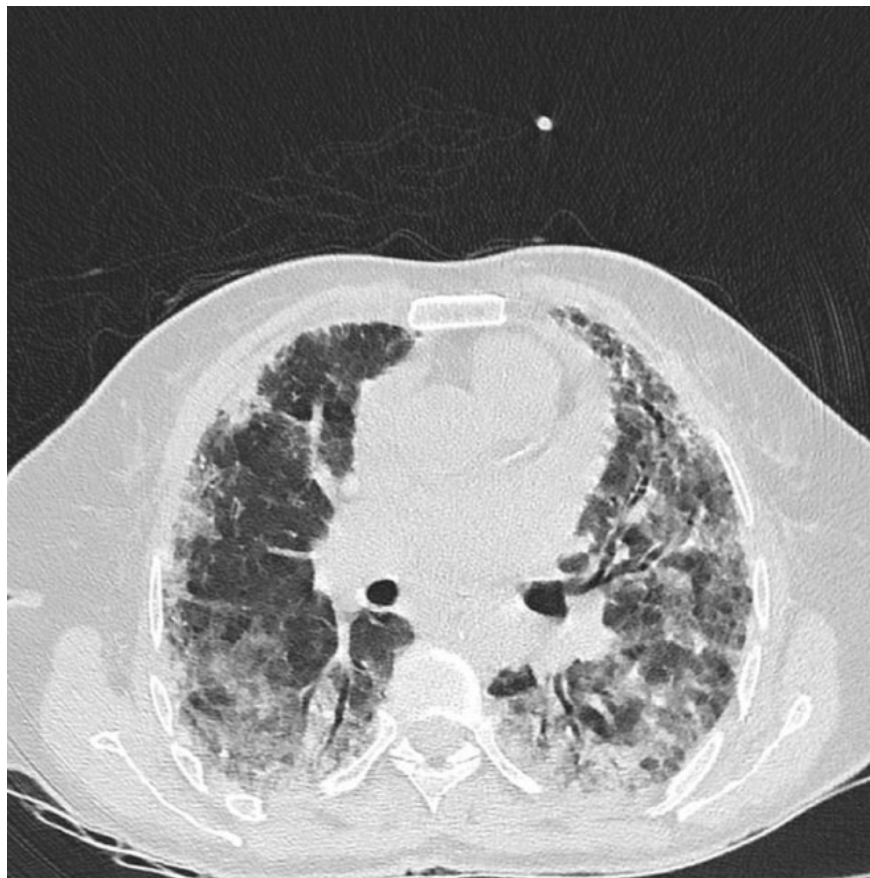


Fig. 2: there is evidence of bilateral multiple diffuse patchy confluent consolidation and ground-glass opacity with interlobular septal thickening (crazy paving appearance) associated with subpleural involvement in some areas

The patient was discharged with good general conditions and relative improvement of coughs and dyspnea. Four week after discharge, coughs and dyspnea were completely recovered.

### Case 3

A 25 years old Iranian pregnant housewife – known case of sickle cell anemia – presented in the sixth week of pregnancy with myalgia, fever and chills, and dry coughs since a week ago. She didn't respond to outpatient treatment and didn't receive the COVID-19 vaccine. Vital signs were normal: temperature of 37.5°C, respiratory rate of 15/min, blood pressure of 110/90 mmHg, and SPO2 of 98%.

In physical examination, the conjunctiva was pale and lung auscultation was clear. Based on the history and symptoms of the patient, PCR tests for COVID-19 and influenza were taken which were positive simultaneously. The patient has been treated with oseltamivir 75mg PO every 12 hours for five days and remdesivir 200mg STAT and 100mg daily through IV-line for three days. The patient was discharged with good general conditions and advised for outpatient follow-up. A week later, coughs and myalgia were completely recovered.

Results of laboratory tests of three patients are summarized below.

Test	Case 1	Case 2	Case 3
BS (mg/dL)		275	
Urea (mg/dL)	36	94	20

Test	Case 1	Case 2	Case 3
Creatinine (mg/dL)	1.2	1.4	0.6
SGOT (U/L)	28	17	40
SGPT (U/L)	11	19	38
ALP (U/L)	245	270	271
LDH (U/L)	460	518	240
WBC ( $\times 10^3$ )	10.5	14.1	3.5
Neutrophil (%)	78.1	84.9	83.5
Lymphocyte (%)	18.8	10.6	12.7
Hb (g/dL)	10.4	7.3	7.5
MCV (fL)	77.9	77.5	68
Plt ( $\times 10^3$ )	225	358	145
Na	128	134	
K	4.4	4.7	
CRP (mg/dL)	23	66.67	12
D-Dimer		365.45	450
ESR (mm/hour)	68	55	25
HIV-P24	0.09		

## Discussion

Respiratory co-infections are common and simultaneous infections with two viruses are accompanied by effects on the host and the synergism of viruses. It will affect the immune response and outcome of the treatment [2]. Common symptoms in patients with covid-19 and influenza co-infections include fever, cough, and shortness of breath; Considering the exact transmission mechanism of these two viruses, it is necessary to perform appropriate and correct tests and timely diagnosis to differentiate and proper treatment [6]. Furthermore, bacterial along with viral infection can bring about other problems [5]. Hence, appropriate diagnosis and treatment are vital for patient recovery and suitable clinical outcomes. According to the results of a systematic review study, co-infection with influenza and covid-19 may be associated with a predisposition to secondary bacterial infection, which can increase clinical outcomes [7]. In reported cases, COVID-19, influenza co-infection and TB co-infection of case 1 along with comorbidities and pregnancy represented situations entailing on-time diagnosis and appropriate management. The dose and duration of the effective treatment and monitoring of the patient's symptoms and conditions are other factors helping clinicians in achieving an optimal clinical outcome.

## Conclusion

In the cases presented here, it can be inferred that combined treatment for COVID-19 and influenza together with bacterial TB – in case TB infection is suspected or confirmed – can be useful for the management of the infection and achieving suitable outcomes. In addition, synergism of the pathogens and comorbidities of the patient are factors that were optimally controlled by means of the treatment regimens indicated for each disease.

## Ethics Approval

Hormozgan University of Medical Sciences Ethical Committee approved the study under the ethical code IR.HUMS.REC.1401.011.

## Consent for Publication

Written informed consent was obtained from the patient to publish this case report and any accompanying images. A copy of the written consent is available for review by the Editor-in-Chief of this journal.

## Availability of Data and Materials

The data sets used during the current study are available from the corresponding author upon reasonable request.

## Competing Interests

The authors declare no conflict of interest.

## Funding

This research did not receive any specific grant from funding agencies in the public, commercial, or not-for-profit sectors.

## Authors' Contributions

EB, PD, MHA and SD contributed to the design of the study and revised and approved the final draft of the manuscript. EB contributed to data acquisition and data analysis and revised and approved the final draft of the manuscript. AJ wrote the manuscript and revised and approved the final draft of the manuscript.

## Acknowledgments

We thank our counselors in the Shahid Mohammadi Hospital in Bandar Abbas.

## References

- [1] Jing R, Vunnam RR, Schnaubelt E, Vokoun C, Cushman-Vokoun A, Goldner D, Vunnam SR. Co-infection of COVID-19 and influenza A in a hemodialysis patient: a case report. *BMC Infectious Diseases*. 2021 Dec;21[1]:1-6.
- [2] George JA, AlShamsi SH, Alhammadi MH, Alsuwaidi AR. Exacerbation of influenza a virus disease severity by respiratory syncytial virus co-infection in a mouse model. *Viruses*. 2021;13[8]:1630.
- [3] Ali R, Patel A, Chan KH, Veeraballi S, Slim J. A case series of SARS-CoV-2 and influenza co-infection. *Cureus*. 2021 Aug 31;13.
- [4] Luo M. Influenza virus entry. *Viral Mol Mach*. 2012;201–21.
- [5] Lew S, Manes P, Smith B. Coinfection with SARS-CoV-2 and influenza A virus in a 32-year-old man. *Am J Case Rep*. 2020;21:e926092-1.
- [6] Shah MU, Sohail A, Jaffry AA, Khurshid M, Nashwan A, Ullah I. Influenza A and COVID-19 coinfection: A systematic review of cases. Available at SSRN 4077063. 2022.
- [7] Li Y. The role of respiratory co-infection with influenza or respiratory syncytial virus in the clinical severity of COVID-19 patients: A systematic review and meta-analysis. *Authorea Preprints*. 2022 Apr 8.